

## **Egyptian Dermatology Online Journal**

### **Volume 5 Number 2**

### **Squamous Cell Carcinoma Arising on Extensive and Chronic Lupus Vulgaris**

**Pathak D.\* and Thapa A\*\***

#### **Egyptian Dermatology Online Journal 5 (2): 16**

\* Consultant Dermatologist, Delhi Dermatology Group Kubba, New Delhi, India.

\*\* Former Senior Resident, Department of Surgery, B.P. Koirala Institute of health sciences, Dharan, Nepal.

**e-mail:** [drdeeparapathak@yahoo.com](mailto:drdeeparapathak@yahoo.com)

**Submitted:** November 24<sup>th</sup>, 2009

**Accepted:** November 30<sup>th</sup>, 2009.

#### **Abstract**

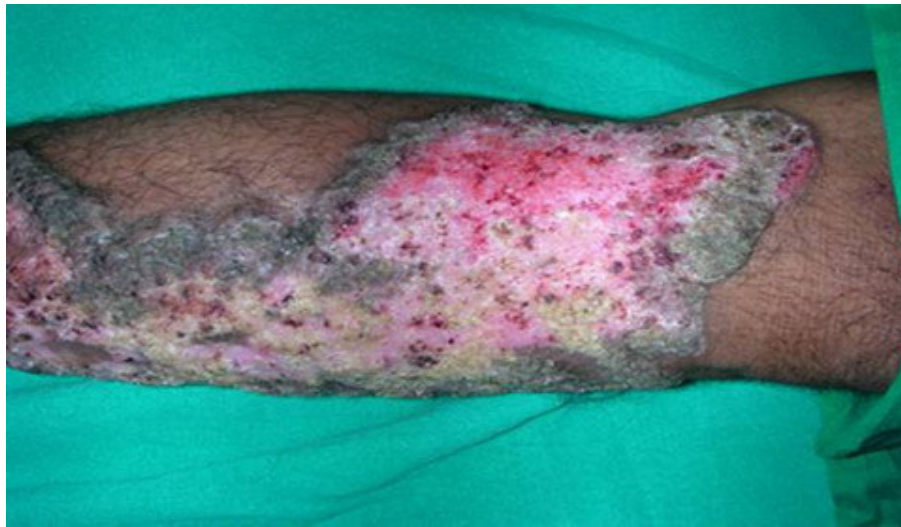We present here a case of a 30 years old farmer presenting with multiple verrucous plaques over the dorsum of feet, shins, trunk, neck and face for 10 years and a large ulcerated growth on left hand and forearm for 6 years. Physical examination confirmed the historical details and revealed enlarged hard left axillary lymph nodes. Mountoux test was 20mm. Biopsy from the fungating mass and plaques was suggestive of squamous cell carcinoma and lupus vulgaris respectively. Diagnosis of lupus vulgaris (LV) with Squamous cell carcinoma (SCC) was made. Anti-tuberculous treatment (ATT) was started and was subsequently evaluated by surgeons for amputation and wide field lymph node dissection. This case together with various anecdotal reports in literature reflects the need to know possibility of development of malignancy in chronic lupus patients and mandates regular clinical follow up for early detection and the chance of complete cure.

#### **Case Report**

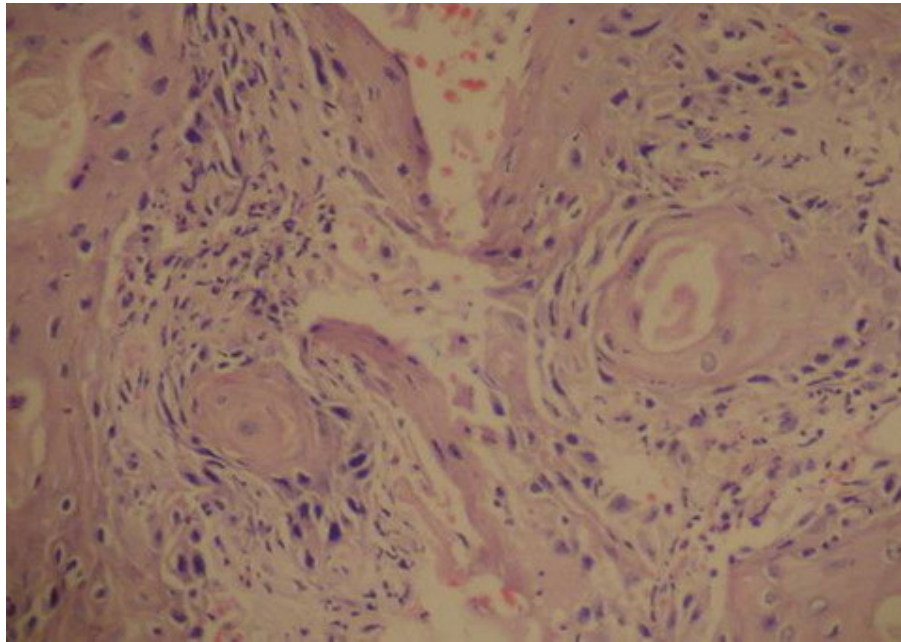
Lupus vulgaris is extremely chronic, and without therapy extends over many years and can lead to serious complication of development of carcinoma.

A 30 years old male farmer presented with multiple plaques with verrucous surface over the dorsum of feet, shins, trunk, neck and face for 10 years and one large ulcerated growth on the left hand and forearm for 6 years. Physical examination revealed a large fungating growth extending from the left dorsum of hand to mid forearm. Multiple hyperpigmented plaques with varying sizes ranging from 5cm x 8cm to 15cm x 20cm with well defined irregular raised margins and verrucous surface were detected (**Figure 1**). Left axillary lymph nodes were enlarged and hard on palpation. Differential diagnosis of lupus vulgaris with SCC (squamous cell

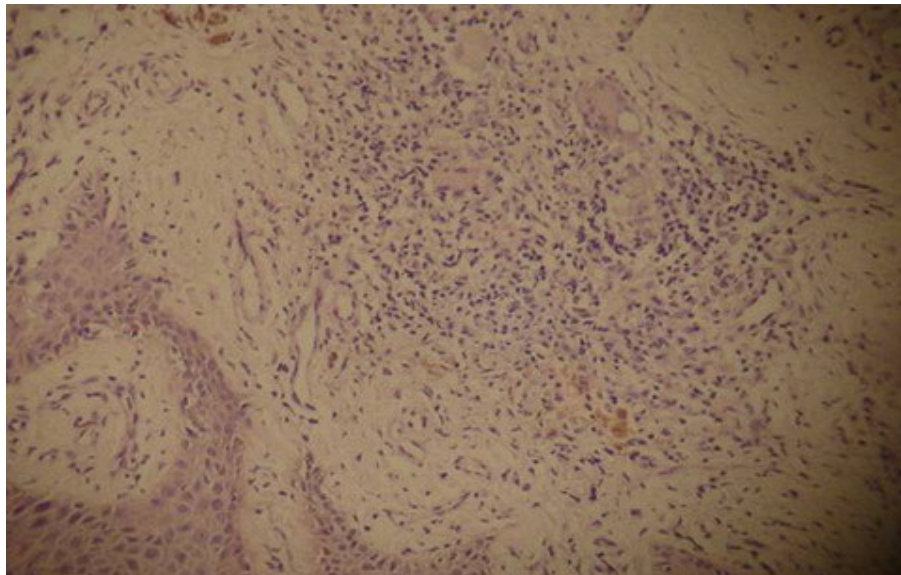
carcinoma) or chromoblastomycosis with SCC was made. Wedge biopsy from the fungating mass showed squamous cell carcinoma infiltrating into the stroma, well developed keratin pearls and squamous epithelial cells with large hyperchromatic irregular nuclei, consistent with the diagnosis of squamous cell carcinoma (**Figure 2**). Punch biopsy from a plaque showed granulomas in the mid-dermis of different sizes, consistent with lupus vulgaris (**Figure 3**). Mountoux test showed induration of 20 mm in diameter. Fungal cultures and KOH smear were negative. Chest x-ray and other laboratory investigations including complete blood count, random blood sugar and renal function tests were within normal limits. Based on the clinical and the histopathological features and the strong positive Mountoux test, diagnosis of lupus vulgaris with squamous cell carcinoma was made. CAT III antituberculous treatment including Isoniazide, Rifampicin, Pyrazinamide for 2 months and Isoniazide and Ethambutol for 6 months was advised. The patient was evaluated in the surgery department for amputation and wide field lymph node dissection.



**Fig 1:** Verrucous plaques with hyperpigmented well defined irregular raised margins.



**Fig 2:** Wedge biopsy showing well developed keratin pearls and squamous epithelial cells with large hyperchromatic irregular nuclei, consistent with squamous cell carcinoma.



**Fig 3:** Punch biopsy from a plaque showing granulomas in the mid-dermis of different sizes, consistent with lupus vulgaris.

## Discussion

Lupus vulgaris, an extremely chronic and progressive form of tuberculosis of skin occurs in patients with good immunity[1]. Cutaneous lesions of lupus vulgaris may be complicated by the development of malignancies, the majority of which are squamous cell carcinoma, sometimes referred to as lupus carcinoma[2]. The incidence of carcinoma varies from 0.5% to 10.5%. The interval from the onset of lupus vulgaris to the occurrence ranges from 2 to 79 years. In our patient it took 10 years to develop. There are two types of lupus carcinoma; one originates from the tuberculous tissue and the other from lupus scars.[2,3,4] In our patient, the malignant degeneration, probably, occurred from the tuberculous tissue. The etiology of lupus carcinoma remains unknown. X-ray therapy is an important factor in carcinogenesis. Chronic inflammation through reactive oxygen species produced by activated inflammatory cells, cicatricial changes, physical and chemical trauma and sunlight are other factors giving rise to carcinoma[5,6]. Our patient was a farmer by occupation therefore sunlight, trauma and chronic inflammation might have played role in the oncogenesis. According to Ramesh et al [7], the diagnosis of cutaneous tuberculosis basically depends on clinical findings, a strong tuberculin reaction test and response to antituberculous therapy. On the basis of clinical findings, histopathological findings and strong Mountoux test, diagnosis of squamous cell carcinoma arising on chronic and extensive lupus vulgaris was made.

Category III (Directly Observed Treatment Short-course DOTS regimen) anti-tubercular treatment for 6 months is advised for cutaneous tuberculosis. This regimen included 2 months daily intensive course of Isoniazide, Pyrazinamide and Rifampicin followed by 4 months of thrice a week continuation phase of Isoniazide and Rifampicin. Response to treatment is quite variable. A good therapeutic response supports the diagnosis of tuberculosis as a cause. Pyridoxine should be used (40 - 50mg daily) to avoid convulsions on the newborn.

Squamous cell carcinoma needs surgical referral. Till date, effective treatment is elusive. Small size lesion can be removed or destroyed using electrodissection and curettage or cryosurgery. Mohs surgery has shown highest cure rate. It is advised for lesions larger than 2 cm across, poorly defined margins, recurrent lesions or facial or genital lesions. Larger lesions are difficult to manage and can have recurrence rates as high as 50%. If surgically removable, lymph node dissection is advised where lymph nodes are enlarged and/or hard. Systemic chemotherapy and radiotherapy are options for widely disseminated lesions.

This case has been reported because of its uncommon presentation. This is all the more important in Asian countries like India, Nepal which have large population suffering from tuberculosis. Here the population is more exposed to this fatal complication due to illiteracy and poor socio-economic status, leading to poor follow up. These factors compounded by scarcity of trained dermatologists, delay the time of detection of malignant change in such lesions. This report together with multiple anecdotal reports mandates frequent follow up in chronic lupus. Early diagnosis is necessary, which could save such patients from being handicapped and subsequent morbidities and provide them with a chance of complete cure.

## References

1. Tappeiner G, Wolff K. Tuberculosis and other mycobacterial infections. In : Freedberg IM, Eisen AZ, Wolff K, Austen KF, Goldsmith LA, Katz SI editors- Fitzpatrick's Dermatology in general medicine. Vol 2. 6<sup>th</sup> Ed. New York; McGraw hill, 2003: 1933- 1950.
2. Kanitakis J, Audeffray D, Claudy A. Squamous cell carcinoma of the skin complicating lupus vulgaris. J Eur Acad Dermatol Venereol. 2006; 20: 114- 116
3. Ekmekci TR, Koslu A, Sakiz D, et al. Squamous cell carcinoma arising from lupus vulgaris. J Eur Acad Dermatol Venereol. 2004; 19: 511- 513.
4. Hagiwara K, Uezato H, Miyazato H, et al. Squamous cell carcinoma arising from lupus vulgaris on an old burn scar: diagnosis by polymerase chain reaction. J Dermatol 1996; 23: 883- 889.
5. Forstrom L. carcinomatous changes in lupus vulgaris. Ann Clin Res 1969; 1: 213- 219.
6. Motswaledi MH, Doman C. Lupus vulgaris with squamous cell carcinoma. Cutan Pathol. 2007; 34: 939- 941
7. Ramesh V, Mishra RS, Beena KR, et al. A Study of cutaneous tuberculosis in children. Padiatr Dermatol. 1999; 16: 264- 269.